

Custom Made Acrylic Vaginal Stent As An Adjunct After Vaginoplasty For A Young Female With Agenesis Of Vagina

Dr. Tanvi Jaiswal

Lecturer, Dept of Prosthodontics

Dr. S R Godbole

HOD, Dept of Prosthodontics

Dr. Seema Sathe

Professor, Dept of Prosthodontics

Abstract: Vaginal agenesis is one of the major congenital anomalies of female genital tract. Most commonly it is associated with (MRKH) Mayer- Rokitansky-Kuster- Hauser syndrome. The correction of vaginal agenesis requires the creation of neovaginal cavity. After reconstruction of space for vagina surgically, a long term use of stent is required to maintain vaginal width and depth and to prevent contraction. This article describes a case of nonsyndromic agenesis of vagina in a 14 year old girl and its surgical management using custom fabricated acrylic vaginal stent.

Keywords: Vaginal stent, vaginal agenesis, vaginoplasty, MRKH syndrome

I. INTRODUCTION

Vaginal agenesis is one of the major congenital anomalies of female genital tract. Mayer- Rokitansky-Kuster- Hauser syndrome, a congenital anomaly of the female genital tract, is characterized by vaginal agenesis. This syndrome is estimated to occur in approximately 1 in every 4500 females¹.

Patient with vaginal agenesis can be treated by both surgical and non surgical procedures. Irrespective of the procedure done, prosthetic vaginal dilators or long term vaginal stents are required to prevent the possible contraction of the reconstructed vagina and to maintain vaginal width and depth to avoid vaginal stenosis.² Vaginal stents are used to accomplish tissue expansion, customized stents are made with increasing measurements in its length and diameter over a period of time. However vaginal stents are used post operatively not only to maintain vaginal depth and width and to prevent contraction or shrinkage and structure of neovagina but it also serves as haemostat. Vaginal dilators are used for non surgical procedures for creation of neovagina for patients with complete mullerian agenesis is usually considered the first line of treatment.

This article presents the fabrication of a customized acrylic vaginal stent for a young female patient of 14 years of age managed surgically for vaginal agenesis.

II. CASE REPORT

A 14 years old young female patient was referred from dept of gynaecology to department of Prosthodontics, Sharad Pawar Dental College, Sawangi (M) Wardha for fabrication of vaginal stent. The girl was unmarried, accompanied by her parents, reported with a chief complaint of pain in lower abdomen since last 2 week and history of primary amenorrhea. So the patient had reported to dept. Of gynecology for the same

On examination, patient had normally developing secondary sexual characters. Gynecological examination showed the presence of vaginal agenesis, so vaginoplasty was planned for this patient and patient was referred from gynaecology department for fabrication of vaginal stent. The dimensions for the stent were not specified and was to be decided intraoperatively depending on the tissue resected at time of surgery.

III. FABRICATION OF STENT

- ✓ After resection of the tissue, preliminary impression was made immediately with impression compound (Y-DENTS ESQUIRE) to verify the depth and width of impression in the presence of concerned surgeon.(Fig 1)
- ✓ Then a index of impression was made with poly vinyl impression material (Dentsply, india) to form a mould. (Fig 2)
- ✓ 2mm of impression compound was scraped from all aspects of impression. Auto polymerizing acrylic resin (DPI, India) was mixed in a thin consistency and poured it in a mould fabricated with the help of PVS impression material.(Fig 3)
- ✓ Scraped impression was then seated in mould filled with autopolymerizing resin till acrylic resin polymerized.
- ✓ After the polymerization of resin, whole unit was immersed in hot water and impression compound was removed to obtain a hollow cone shaped vaginal stent. (Fig 4)
- ✓ Base of cone was packed with autopolymerizing resin and a horizontal through and through hole was created so that guaze piece could be tied for proper positioning of the stent. Stent was delivered to the patient and again after a week patient was referred from dept of gynaecology for fabrication of a vertical through and through hole in the stent for proper drainage of vaginal secretions. (Fig 5)
- ✓ The base end was cut and fabricated again to form a funnel shape, so that secretions could be drained out properly.(Fig 6)
- ✓ Hole was drilled through and through from tip of stent passing to the base of stent and finally stent was delivered to patient for maintaining patency of vagina for temporary period of 2 months depending on healing. (Fig 7, 8)
- ✓ Patient was instructed about proper care and maintainance of prosthesis.



Figure 1

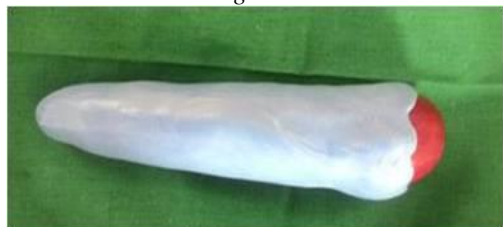

Figure 2



Figure 3

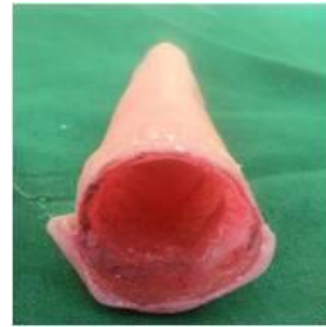


Figure 4

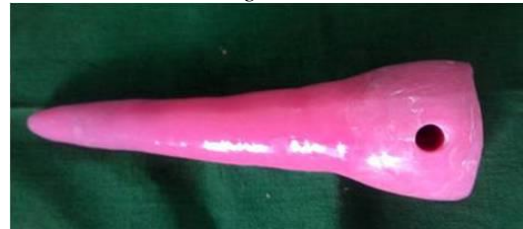

Figure 5

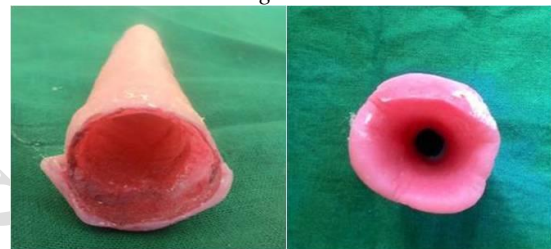

Figure 6

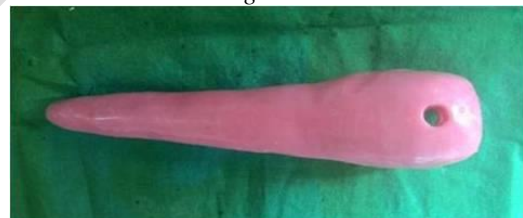

Figure 7



Figure 8

IV. DISCUSSION

Developmental absence of vagina is a major congenital anomaly of female genital tract that can occur as isolated developmental defect or as a part of complex anomaly. Vaginal agenesis commonly form part of MRKH syndrome, first described by Hause and Scheiner in 1961. It is often associated with anomalies of the renal and skeletal system and with normal female genotype, phenotype and normal endocrine status.

Irrespective of procedure prosthetic vaginal dilators or long term stents are required to prevent the possible contraction of the reconstructed vagina and to maintain

vaginal width and depth to avoid stenosis. In present case hollow vaginal stent was fabricated with autopolymerizing resin for a patient of vaginal agenesis.

Dr. Jothikumar kamalakkannan, Varsha Murthy in 2015 fabricated vaginal stent with silicone and concluded that silicone vaginal stent is more comfortable to patient due to lighter weight as compared to autopolymerizing resin acrylic stent.

So we tried to fabricate a hollow acrylic stent to reduce the weight of acrylic stent which we found was very less ie:- 41 gms and patient was more comfortable with light weight stent. This also proved to be more effective as compared to silicone vaginal stent.

V. CONCLUSION

Prosthetic vaginal stent to a patient of vaginal agenesis is a good option for maintaining the patency of vagina during complete healing period. It is simple, quick and cost effective technique as compared to fabrication of silicone stent. This

mould can be easily procured by any clinician from a prosthodontic, prior to surgery or at time or after surgery.

REFERENCES

- [1] Kannan RB, Nayak A, Varadhan et al, Mayer-Rokitansky-Kuster-Hauser syndrome and pituitary adenoma: a co incidence; Endocr Abstract 2014; 34, 143.
- [2] Dr. Jothikumar Kamalakkannan, Varsha Murthy, customized silicone vaginal stent, Journal of obstetrics and gynaecology of india, July-Aug 2015, 65(4); 281-283.
- [3] Manu Rathee, Priyanka Boora, Renu Kadu, Custom fabricated acrylic vaginal stent for vaginal agenesis, Journal of Human reproductive science, vol 7, issue 4, oct-dec 2014.
- [4] Capraro VJ, Gallego MB, Vaginal agenesis, AM J Obstet Gynecol 1976; 124: 98-107.
- [5] Mobus VJ, Kortenhorn K, Kreienberg R, Freidberg V, Long term results after operative correction of vaginal aplasia. Am J obstet Gynecol 1996; 175:6, 17-24.

IJIRAS